

A comparative study on the effect of ultrasound and interferential therapy for peri arthritis of shoulder (adhesive capsulitis)

Prof. Dr.K.Madhava Reddy, Phd., D.Sc., Principal ¹, Prof. Dr.S.Gopi Kannan, BPT²., Sri Lakshmi Institute of Medical Sciences College of Physiotherapy, Kavali.

Abstract

A total of 20 patients who fulfilled the eligible criteria were randomly allocated to control group and experimental group using block randomization. Experimental group patient received ultrasound and control group received interferential therapy separately. Both the groups were given Codman's exercise, Finger ladder exercise and passive capsular stretching. VAS and UEFI were taken for both the groups before and after treatment as outcome measures. Comparison of outcome measures was done between both the groups after 2 weeks. There is no significant difference between experimental and control groups in terms of UEFI ($p=0.676$) and VAS ($p=0.467$) scores at 14th day of intervention. Within group comparison showed significant improvement in UEFI ($p=0.009$ for control and $p=0.005$ for experimental group) and VAS ($p=0.010$ for control and $p=0.005$ for experimental group) scores at 14th day of intervention.

Key words

Adhesive capsulitis, Combination Therapy, Pulsed Ultrasound, Interferential current

Introduction

Adhesive capsulitis (AC) is a soft tissue disorder resulting in pain, stiffness, and progressive loss of active and passive range of motion. In AC, joint capsule adheres to humeral head due to contraction of glenohumeral joint capsule (Jewell DV 2009, Ewald A 2011). Patients with AC have difficulty in activities involving either arm elevation or bringing it back (e.g., dressing, grooming, and performing overhead reaching activities) for a longer time period (several months or even years). Estimated prevalence of AC in general population is 2- 4%. Female and type 2 diabetes mellitus subjects are most commonly affected (Vermeulen HMV 2006). Diabetes, immobilization of the shoulder, shoulder trauma, cervical disk disease, cardiovascular and pulmonary diseases, hyperthyroidism, and autoimmune diseases are the most common risk factors associated with AC. AC is described as either primary, having an

unknown cause (idiopathic) or secondary, resulting from a known cause or surgical event. The incidence of secondary adhesive capsulitis is higher than that of primary. Recent literatures describe adhesive capsulitis into 3 stages, the painful stage (first), the adhesive stage (second), and the resolution stage (third) (Walmsley S 2009). However pain and stiffness may be seen in all the stages and may not follow the stepwise course and up to 10 percent of the patients never recover full range of motion. But this loss of motion is seldom functionally limiting. Classical features of adhesive capsulitis include pain and restricted shoulder joint range of motion. Management of AC includes conservative (nonoperative) and surgical approaches.

Presently ultrasound and IFT are being used together as a combination therapy. It is suggested that when ultrasound and interferential current therapy are given in combination, the advantages/effects of each treatment modality can be achieved. Similar effects are achieved with lower intensities of IFC and even the accommodation effects are reduced (or eliminated). But there is a lack of evidence in literature to support its effectiveness. Tatiana et al. has showed that combination therapy is effective in managing pain and sleep manifestations in adhesive capsulitis (Almeida TF 2003)

Visual analogue scale (VAS) is a numerical scale which measures the pain of the individual. It is a 10cm line with one end marked as Zero(0) indicates no pain and other end with Ten (10) indicates intolerable pain or worst type of pain. Studies show that VAS has high amount of reliability and validity and can be used as a measurement tool.

Though there are many interventions prescribed in the management of adhesive shoulder, the evidences are still lacking or the results are controversial. First choice of the treatment is based on a rehabilitation therapy program that has to follow precise steps leading to functional recovery of the shoulder joint avoiding the need for surgery (Donatelli, 2012). Various studies were done on the treatment of musculoskeletal and shoulder pain(**T Hacer**

Dogru et al,2008, [Cheing GL](#) et al 2008, Fuentes JP et al 2010, Calis HT et al ,2011, Hasan Kerem et al 2016)

Although there are many studies evaluated the efficacy of various treatment, only few studies are done to evaluate the effect of ultrasound therapy and Interferential therapy in adhesive capsulitis this study has been undertaken to compare the effectiveness of ultrasound versus Interferential therapy in the treatment of adhesive capsulitis.

MATERIAL AND METHODS

A total of 20 patients who fulfilled the eligible criteria were randomly allocated to control group and experimental group using block randomization. Experimental group patient received ultrasound and control group received interferential therapy separately. Both the groups were given Codman's exercise, Finger ladder exercise and passive capsular stretching. VAS and UEFI were taken for both the groups before and after treatment as outcome measures. Comparison of outcome measures was done between both the groups after 2 weeks.

SAMPLING CRITERIA

Inclusion criteria

1. Age greater than 35 years.
2. Loss of active and passive glenohumeral joint range of motion.
3. Pain with rapid and unguarded movement.
4. Pain at end of the range in all the direction.
5. Gleno-humeral joint range of motion pain pattern; lateral rotation> abduction> internal rotation (capsular pattern)

Exclusion criteria

1. Rheumatoid arthritis.
2. Fracture of the shoulder complex.
3. Rotator cuff rupture.
4. Tendon calcification.
5. Malignancies in shoulder region.
6. Neurological deficit affecting shoulder function in normal daily activity.

7. Pain or disorders of cervical spine, elbow, wrist, or hand
8. Injection with corticosteroid in the affected shoulder in the preceding 4 weeks.

MATERIALS USED

1. A high chair or couch
2. A foot stool to support patient's feet
3. Ultrasound machine with all accessories.
4. Interferential machine with all accessories.

PROCEDURE

Ethical clearance was obtained from the ethical committee of Sri Lakshmi Institute of Medical Sciences College of Physiotherapy, Kavali. Prior to the commencement of the study, the purpose of the study was explained and a written informed consent was taken from all the participants. 20 subjects based on inclusion and exclusion criteria were selected and divided into two equal groups of ten (n=10). The experimental group patient received ultrasound and control group received interferential current. Exercise was given to all subjects of either group.

Data were analyzed using SPSS version 13. Data were presented in terms of mean and standard deviation. Within groups analysis was performed using Friedman test and Wilcoxon signed rank test. Between groups comparison was performed using Mann whitney test. Significant level was set as $p=0.05$.

RESULTS

Table 1: Baseline data

		Control group	Experimental group	Fishers exact test p value
Age		54.80 ± 13.530	57.30 ± 9.370	0.058
Gender	F	6	3	
	M	4	7	
Duration of symptoms		3.3 ± 1.93	3.8 ± 1.93	

The results of the above table show baseline demographic data of the subjects. Mean age of in control group was 54.80 (S.D \pm 13.530) while in experimental group the mean age of subjects was 57.30 (S.D \pm 9.370). In control group 6 females and 4 males were there while in experimental group 3 females and 7 males were there. There was no significant difference in age, gender and duration of symptoms in subjects of either group.

Table 2: Between group comparison of UEFI and VAS scores pre intervention

	Control group	Experimental group	Mann Whitney test z value	P value
UEFI	41.80 \pm 14.459	52.80 \pm 12.273	1.750	.080
VAS	6.50 \pm 1.650	5.10 \pm 1.287	.606	.544

The results of the above table shows the pre-treatment assessment of UEFI shows mean score of 41.80 (S.D \pm 14.459) and of VAS shows mean score of 6.50 (S.D \pm 1.650) in control group. For the experimental group the mean scores are 52.80 (S.D \pm 12.273) for UEFI and 5.10 (S.D \pm 1.287) for VAS. There was no significant difference in baseline UEFI and VAS score between control and experimental groups.

Table 3: Within group comparison of UEFI and VAS scores- pre and post-intervention

		Pre intervention	Post intervention	Wilcoxon signed rank test p value
UEFI	Control group	41.80 \pm 14.459	48.90 \pm 16.190	0.032
	Experimental group	52.80 \pm 12.273	59.80 \pm 11.622	0.28

VAS	Control group	6.50 ± 1.650	4.70 ± 1.703	0.010
	Experimental group	5.10 ± 1.287	3.40 ± 1.350	0.010

The results of the above table shows within group comparison of UEFI and VAS scores showed significant difference when pre-intervention scores are compared with scores obtained on the 7th day of the intervention

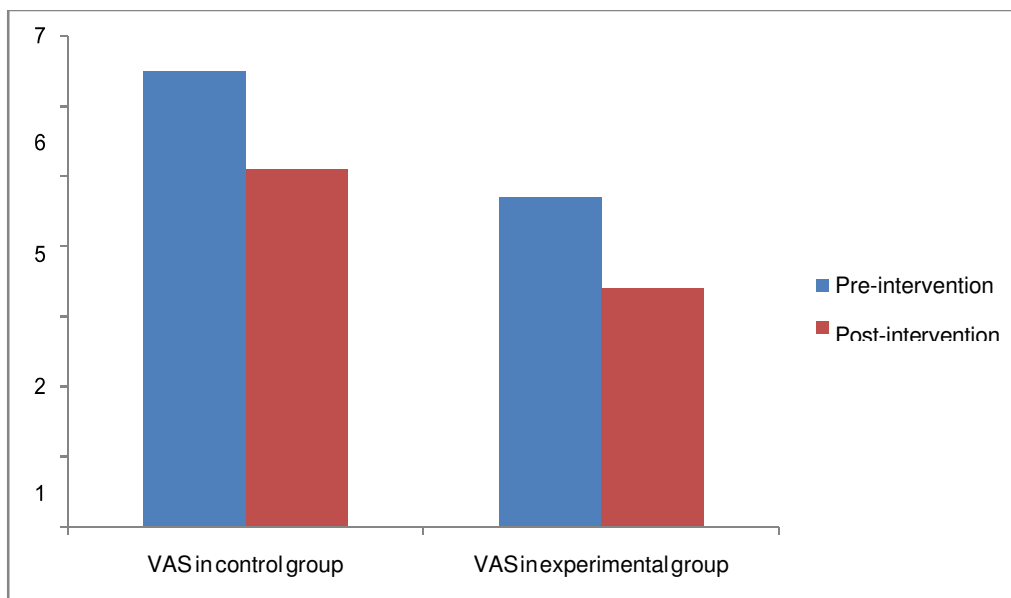
**Table 4: Between groups comparison of UEFI and VAS scores: pre and post-
Intervention**

				Mean of effect between groups	Mann Whitney test z value	p value
UEFI	Change Pre to Post 1	Control group	41.80 ± 14.459 to 48.90 ± 16.190	7.10 ± 9.422	0.76	0.939
		Experimental group	52.80 ± 12.273 to 59.80 ± 11.622	7.00 ± 9.286		
UEFI	Change Pre to Post 1	Control group	6.50 ± 1.650 to 4.70 ± 1.703	1.80 ± 1.687	0.41	0.968
		Experimental group	5.10 ± 1.287 to 3.40 ± 1.350	1.70 ± 1.418		

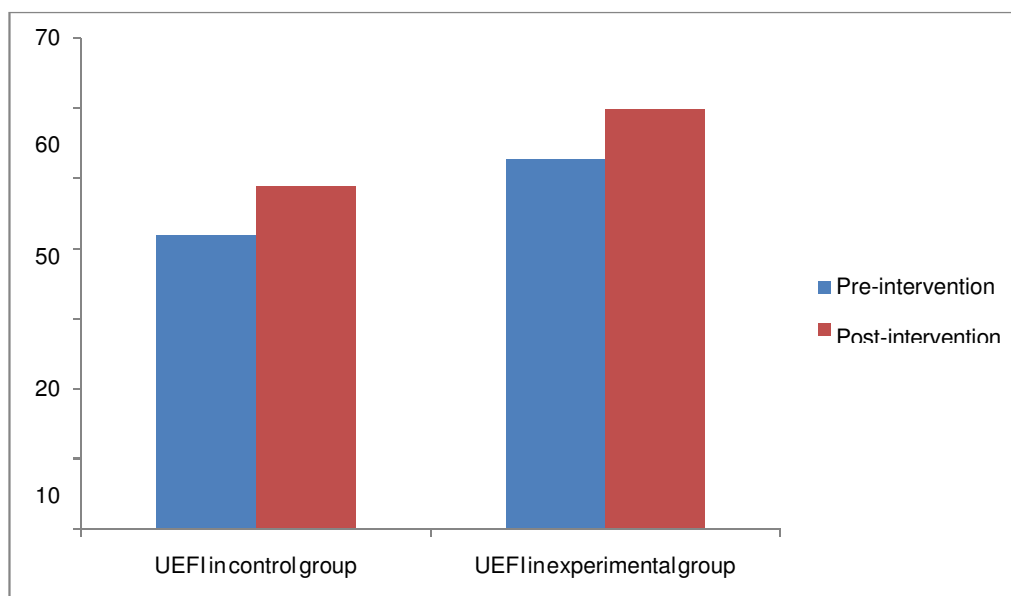
The results of the above table shows between groups comparison of UEFI and VAS scores showed no significant difference when pre-intervention scores were compared with scores obtained on the 7th day of the intervention. Subjects in experimental group were more able in terms of UEFI and VAS scores than of control group. Patients showed improvement on 7th day of intervention in either groups but there was not much difference in improvement between

the groups on the 7th day of intervention. Experimental group subjects showed more improvement in terms of VAS scores where as less improvement in terms of UEFI scores on the 7th day of intervention but the difference in improvement was not significant.

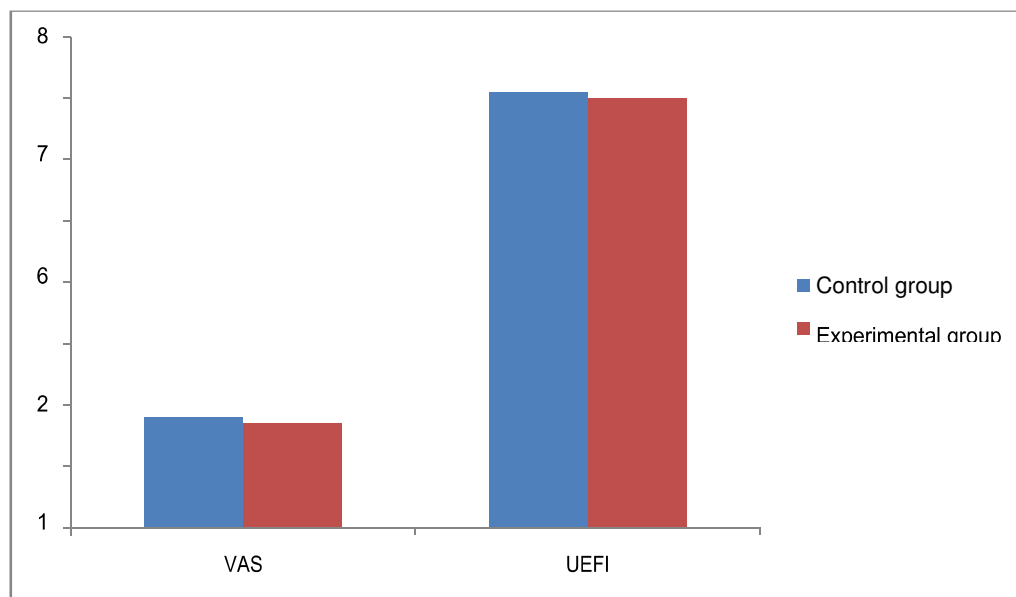
Graph 1: Mean Graph showing within group comparison of pre and post-intervention VAS scores



Graph 2: Mean Graph showing within group comparison of pre and post-intervention UEFI scores



Graph 3: Mean Graph showing between group comparison of pre and post-intervention VAS and UEFI scores



DISCUSSION

In this study the researcher aims to compare the effect of ultrasound Interferential therapy in Periarthritis (Adhesive capsulitis) of shoulder. To our knowledge, this is the first study addressing the effects of electrotherapy in adhesive capsulitis, combining two physical modalities; interferential current (IFC) and ultrasound (US). Mean age of in control group was 54.80 (S.D \pm 13.530) while in experimental group the mean age of subjects was 57.30 (S.D \pm 9.370). In control group 6 females and 4 males were there while in experimental group 3 females and 7 males were there. There was no significant difference in age, gender and duration of symptoms in subjects of either group. In the present study a mean improvement of 1.80 (S.D \pm 1.687) in VAS scores ($p= 0.010$) and 8.70 (S.D \pm 9.534) in UEFI scores ($p=0.009$) in control group and a mean improvement of 1.80 (S.D \pm 0.789) in VAS scores ($p=0.005$) and 9.60 (S.D \pm 6.310) in UEFI scores ($p=0.005$) was found in experimental group. In the present study we found a significant improvement in VAS and UEFI score in both the groups. So, it can be argued that the IFC parameters used in the present study may suit better for the treatment of AC. But there is a need of future study to

compare these parameters with other IFC parameters as well as placebo. A RCT done by Van Der Heijden et al. had found no significant effect of IFC as compared to ultrasound up to 12 months of follow-up. They used two electrodes to deliver 4 KHz sinusoidal biphasic electric current with carrier frequency between 60 to 100 Hz. The present study showed improvements, the reason might be the use of 4 electrodes and carrier frequency of 30 to 100 (Heijden GJMG 1999). Therapeutic ultrasound is frequently used in the treatment of musculoskeletal disorders including adhesive capsulitis (Jewell DV 2009, Ewald A 2011). Ultrasound may benefit the subjects with AC by increasing local metabolism, circulation, extensibility of connective tissue and tissue regeneration (Dogru H 2008, Robertson VJ 2011). The present study shows significant within group improvement in VAS and UEFI scores; this shows that ultrasound has an effect in reducing pain in subjects with AC. However a RCT done by Robertson et al. suggested no significant effect of ultrasound for treating subjects with AC. The reason might be the use of moist heat in both the groups, which may mask the thermal effect of ultrasound (Robertson VJ 2011). In the present study we didn't get any significant improvement in terms of VAS ($p=0.968$) and UEFI ($p=0.939$) scores between the groups. So the present study shows that there is no beneficial effect of ultrasound and interferential therapy over each of them in terms of VAS and UEFI scores in subjects with AC.

However the mean of effect of treatment on the VAS score between the groups shows a mean effect of 1.80 (S.D \pm 1.687, $p=0.467$) in control group and a mean effect of (S.D \pm 1.418, $p=0.968$) in experimental group. Thus experimental group shows more improvement in VAS scores. Inability of the study to get a statistically significant improvement in these is might be due to small sample size, less duration of treatment, or lack of follow up. So future studies with large sample size and of longer duration is essential to get strong decision either to approve or disprove the hypothesis.

Conclusion

Though present study did not prove that ultrasound or interferential current superior over each of them, the study on the same time proves the effectiveness of ultrasound and interferential

current therapy in managing AC. The treatments given in both experimental and control groups have statistically similar effects in patients with adhesive capsulitis.

Bibliography

1. Almeida TF, Roizenblatt S, Silva AAB, Tufik S. The effect of combination therapy (ultrasound and interferential current) on pain and sleep in fibromyalgia. *Pain* 2003;104:665-672.
2. Calis M, Demir H, Ulker S, Kirnap, Duyguhu F, Calis HT. Is intraarticular sodium hyaluronate injection an alternative treatment in patients with adhesive capsulitis? *Rheumatology International* April 2003; 26(6): pp 536-540.
3. Calis HT, Berberoglu N, Calis M: Are ultrasound, laser and exercise superior to each other in the treatment of subacromial impingement syndrome? A randomized clinical trial: *Eur J Phys Rehabil Med.* 2011 Sep;47(3):375-80.
4. Cheing GL¹, So EM, Chao CY. Effectiveness of electroacupuncture and interferential electrotherapy in the management of frozen shoulder : J Rehabil Med. 2008 Mar;40(3):166-70.
5. Dogru H, Basaran S, Sarpel T. Effectiveness of therapeutic ultrasound in adhesive capsulitis. *Joint Bone Spine* 2008; 75(4):445-450
6. Donatelli R. *Physical therapy of the shoulder*, 5th ed. Elsevier-Churchill Livingstone Elsevier, St Louis, 2012.
7. Ewald A. Adhesive capsulitis: a review. *American Academy of Family Physicians* 2011; 83(4):417-422.
8. Fuetnes JP, Olivo SA, Magee DJ, Gross DP. Effectiveness of interferential current therapy in the management of musculoskeletal pain: a systematic review and meta-analysis. *Physical Therapy* 2010;90:1219-1238.

9. Hacer Dogru, Sibel Basaran : Effectiveness of therapeutic ultrasound in adhesive capsulitis: *Joint, bone, spine: revue du rhumatisme* 75(4):445-50 · July 2008
10. Hasan Kerem Alptekin, Tuğba Aydın, Enes Serkan and Mirsad Alkan : Evaluating the effectiveness of frozen shoulder treatment on the right and left sides : *J Phys Ther Sci.* 2016 Jan; 28(1): 207–212.
11. Heijden GJMG van der et al. No effect of bipolar interferential electrotherapy and pulsed ultrasound for soft tissue shoulder disorders: a randomized controlled trial. *Annals of the Rheumatic Disease* 1999;58: 530-540.
12. Jewell DV, Riddle DL, Thacker LR. Intervention associated with an increased or decreased likelihood of pain reduction and improved function in patients with adhesive capsulitis: a retrospective cohort study. *Physical Therapy* 2009; 89: 419- 429.
13. Robertson VJ, Baker KG. A review of therapeutic ultrasound: effectiveness studies. *Physical Therapy* 2001; 81:1339-1350.
14. Vermeulen HMV, Rozing PM, Obermann WR, Cessie SL, Vlieland TPMV. Comparison of high-grade and low-grade mobilization techniques in the management of adhesive capsulitis of the shoulder: randomized controlled trial. *Physical Therapy* 2006; 86:355-368.
15. Walmsley S, Rivett DA, Osmotherly PG. Adhesive capsulitis: establishing consensus on clinical identifiers for stage 1 using the Delphi technique. *Physical Therapy* 2009; 89:906-917.